

3.2.6.3.16	Landmark 16: Medial heel.....	60
3.2.6.3.17	Landmark 17: Centre of first metatarsophalangeal joint impression.....	60
3.2.6.3.18	Landmark 18: Hallux pad centre	61
3.2.6.3.19	Landmark 19: Centre of fifth metatarsophalangeal joint impression	61
3.2.6.3.20	Landmark 20: Calibration dot.....	62
3.2.6.3.21	Landmark 21: Medial calibration point	62

3.2.6.3.16 Landmark 16: Medial heel

Definition: Most medial point of the medial heel border impression




Figure 3.28: Dorsal view of landmark 16

3.2.6.3.17 Landmark 17: Centre of first metatarsophalangeal joint impression

Definition: Centre of the first metatarsophalangeal joint impression




Figure 3.29: Dorsal view of landmark 17

3.2.6.3.18 Landmark 18: Hallux pad centre

Definition:

Centre of the hallux distal phalanx pulp impression



Figure 3.30: Dorsal view of landmark 18

3.2.6.3.19 Landmark 19: Centre of fifth metatarsophalangeal joint impression

Definition: Centre of fifth metatarsophalangeal joint impression



Figure 3.31: Dorsal view of landmark 19

The last three landmarks are placed on the impression platform for calibration purposes.

3.2.6.3.20 Landmark 20: Calibration dot

Definition:

Centre dot on the calibrating plate of the transmitter on the Perspex impression platform

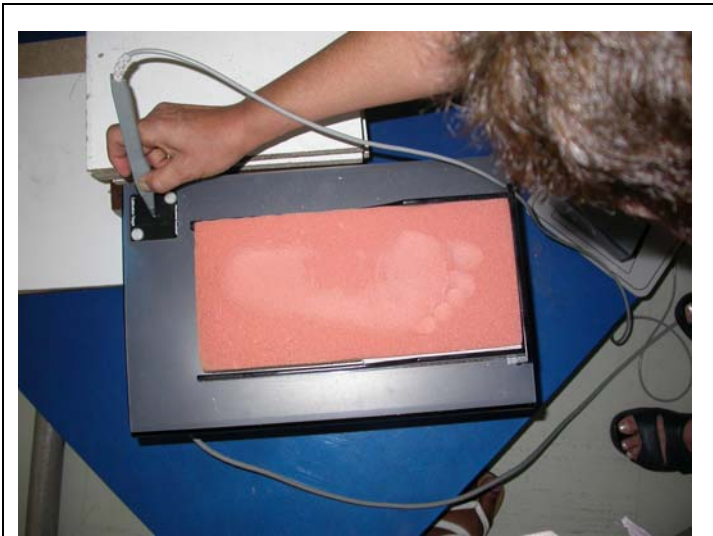

Figure 3.32: Dorsal view of landmark 20

3.2.6.3.21 Landmark 21: Medial calibration point

Definition: Medial corner of the distal frame on the perspex impression platform




Figure 3.33: Dorsal view of landmark 21