

3.2.6.3.1	Landmark 1: Centre of the heel.....	49
3.2.6.3.2	Landmark 2: Tuberosity of the navicular bone.....	50
3.2.6.3.3	Landmark 3: Medial arch.....	51
3.2.6.3.4	Landmark 4: MPJ1	52
3.2.6.3.5	Landmark 5: Hallux.....	52
3.2.6.3.6	Landmark 6: Second toe	53
3.2.6.3.7	Landmark 7: Third toe	53

3.2.6.3.1 Landmark 1: Centre of the heel

Definition: Most proximal point of the heel curve in its sagittal plane bisection.

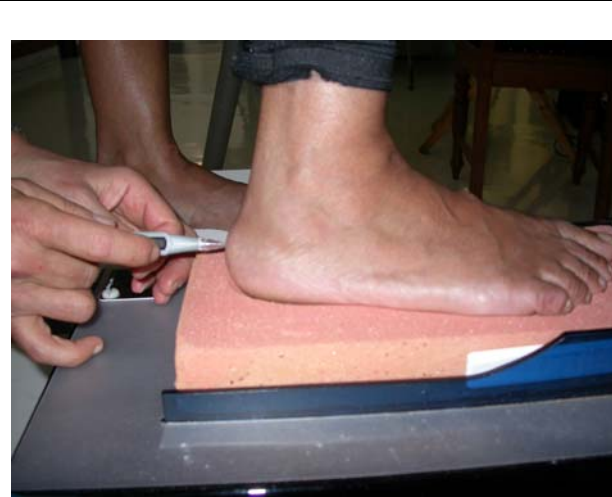


Figure 3.7: Lateral view of landmark 1



Figure 3.8: Landmark 1 in sagittal plane

3.2.6.3.2 Landmark 2: Tuberosity of the navicular bone

Definition: Medial tip of the tuberosity of the navicular bone

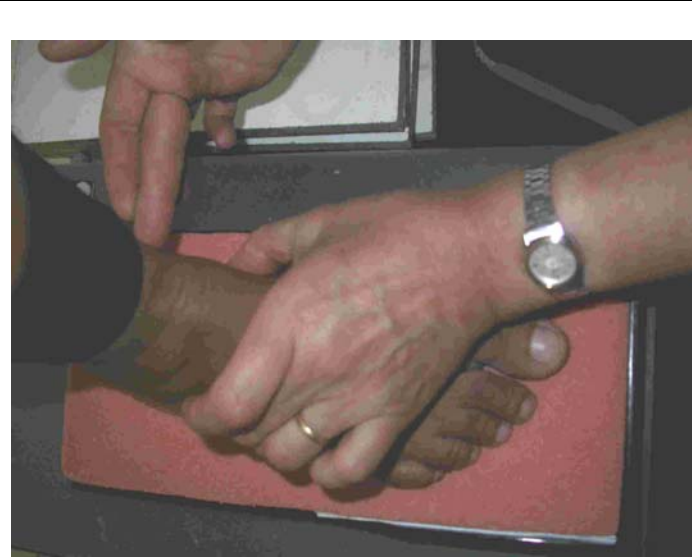

Figure 3.9: Palpation for landmark 2

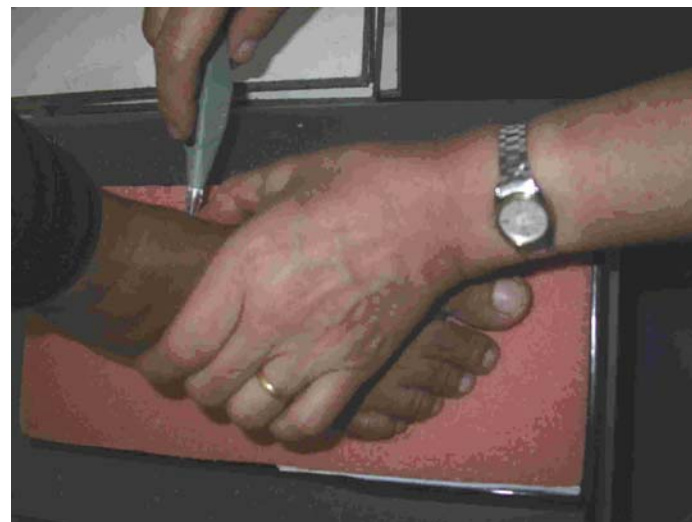

Figure 3.10: Dorsal view of placement of landmark 2

3.2.6.3.3 Landmark 3: Medial arch

Definition: Highest dorso-medial point of the medial longitudinal arch




Figure 3.11: Dorsal view of landmark 3



Figure 3.12: Medial view of landmark 3

3.2.6.3.4 Landmark 4: First metatarsophalangeal joint

Definition:

Widest part of the foot in the sagittal plane at the first metatarsophalangeal joint.

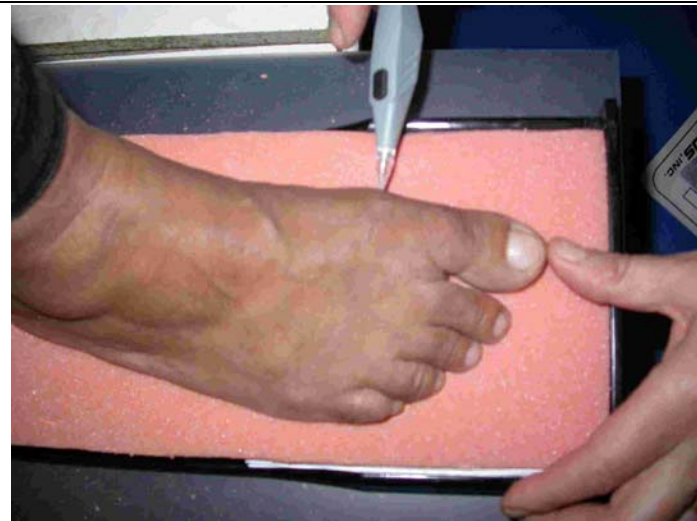

Figure 3.13: Dorsal view of landmark 4

3.2.6.3.5 Landmark 5: Hallux

Definition: Distal tip of the hallux or big toe

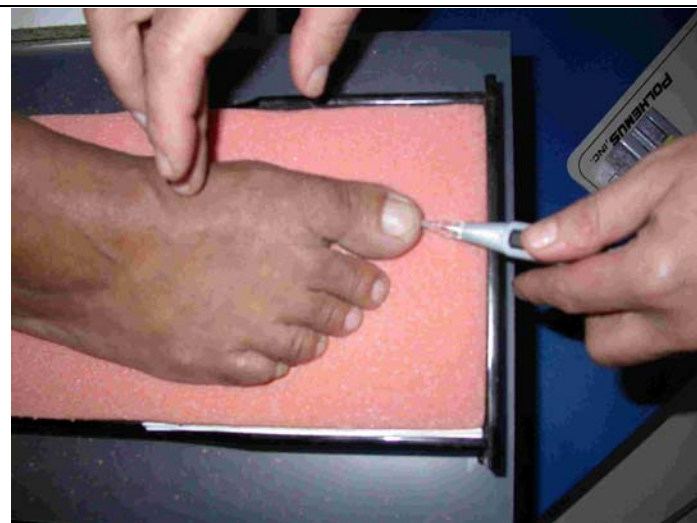


Figure 3.14: Dorsal view of landmark 5

3.2.6.3.6 Landmark 6: Second toe

Definition: Distal tip of the second toe

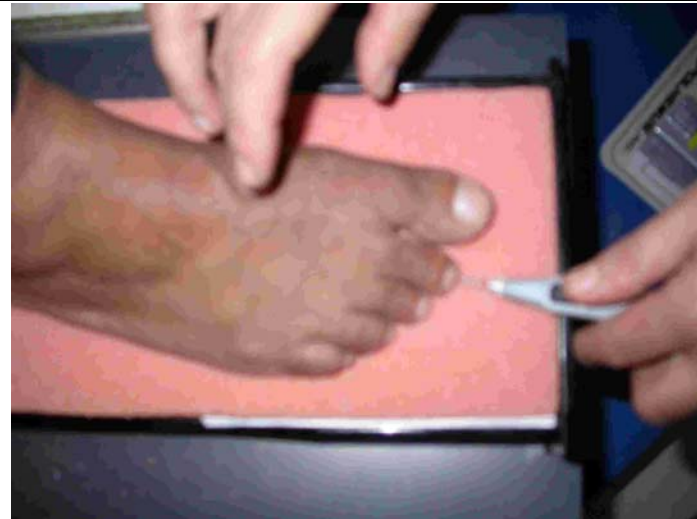

Figure 3.15: Dorsal view of landmark 6

3.2.6.3.7 Landmark 7: Third toe

Definition: Distal tip of the third toe

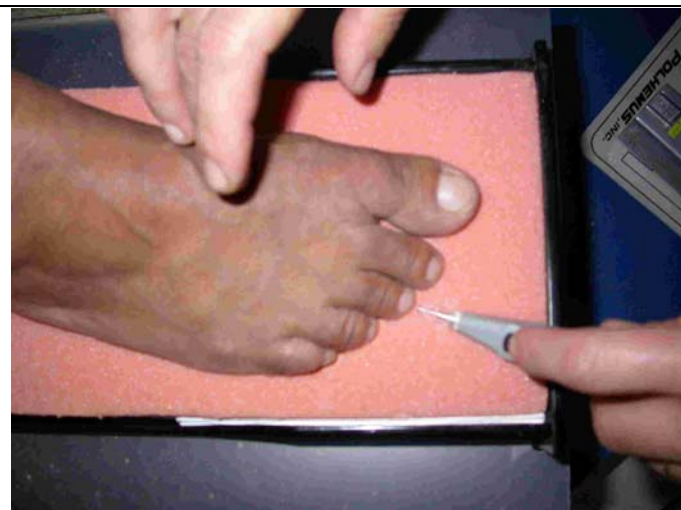

Figure 3.16: Dorsal view of landmark 7